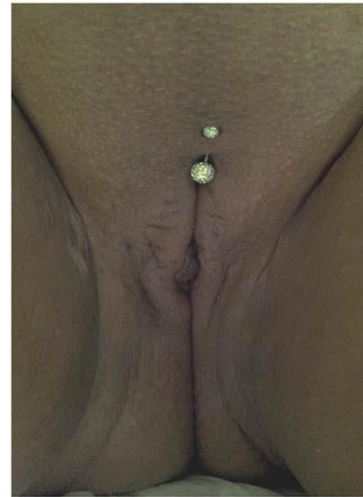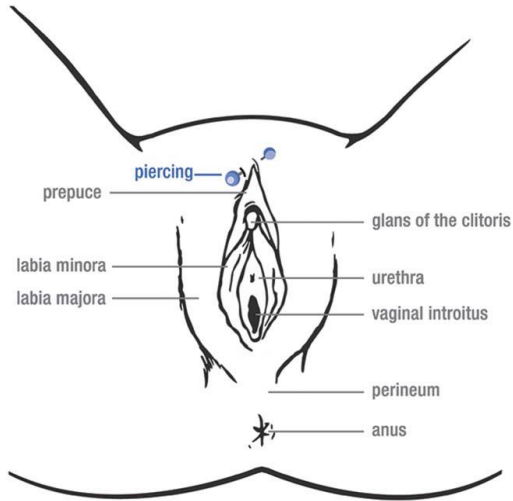


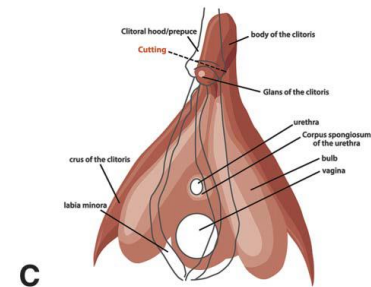
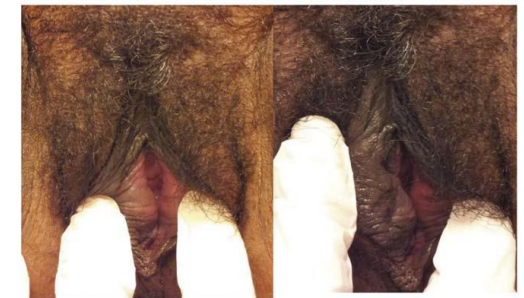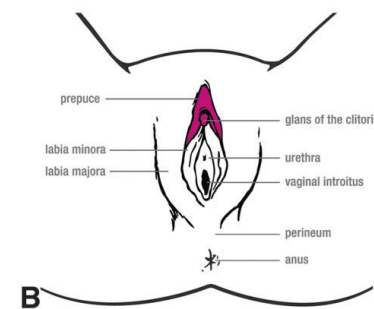
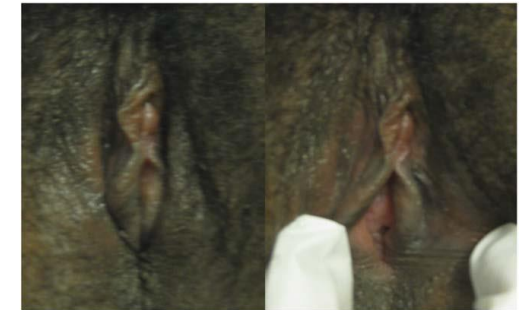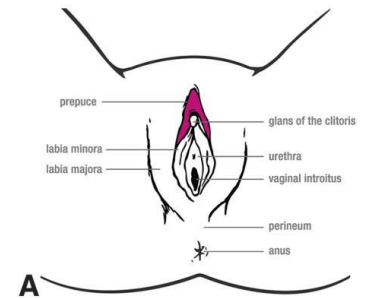
Female genital mutilation type IV: unclassified. All other harmful procedures to female genitalia for nonmedical purposes, for example pricking, piercing (in the figure), incising, scraping, and cauterization. Illustration reprinted from: World Health Organization (WHO). WHO guidelines on the management of health complications from female genital mutilation. Geneva, Switzerland: World Health Organization; 2016. Copyright 2016.



Female genital mutilation type IV: unclassified. All other harmful procedures to female genitalia for nonmedical purposes, for example pricking, piercing (in the figure), incising, scraping, and cauterization

Female Genital Mutilation: A Visual Reference and Learning Tool for Health Care Professionals. Abdulcadir, Jasmine; Catania, Lucrezia; Hindin, Michelle; Say, Lale; Petignat, Patrick; Abdulcadir, Omar *Obstetrics & Gynecology*. 128(5):958-963, November 2016. DOI: 10.1097/AOG.0000000000001686 authorized by Abdulcadir

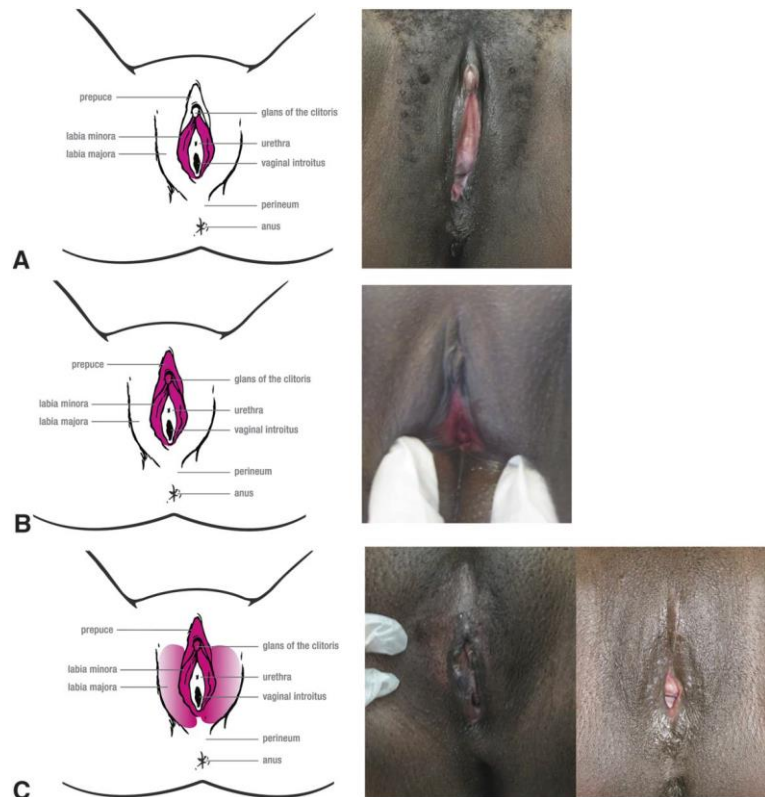
Female genital mutilation type I: partial or total removal of the clitoris or the prepuce or both.



Female genital mutilation type I: partial or total removal of the clitoris or the prepuce or both. A. Female genital mutilation type Ia: removal of the prepuce of the clitoris or clitoral hood (female circumcision). B. Female genital mutilation Ib: removal of the clitoris with the prepuce (clitoridectomy).

Female Genital Mutilation: A Visual Reference and Learning Tool for Health Care Professionals. Abdulcadir, Jasmine; Catania, Lucrezia; Hindin, Michelle; Say, Lale; Petignat, Patrick; Abdulcadir, Omar *Obstetrics & Gynecology*. 128(5):958-963, November 2016. DOI: 10.1097/AOG.0000000000001686 authorized by Abdulcadir

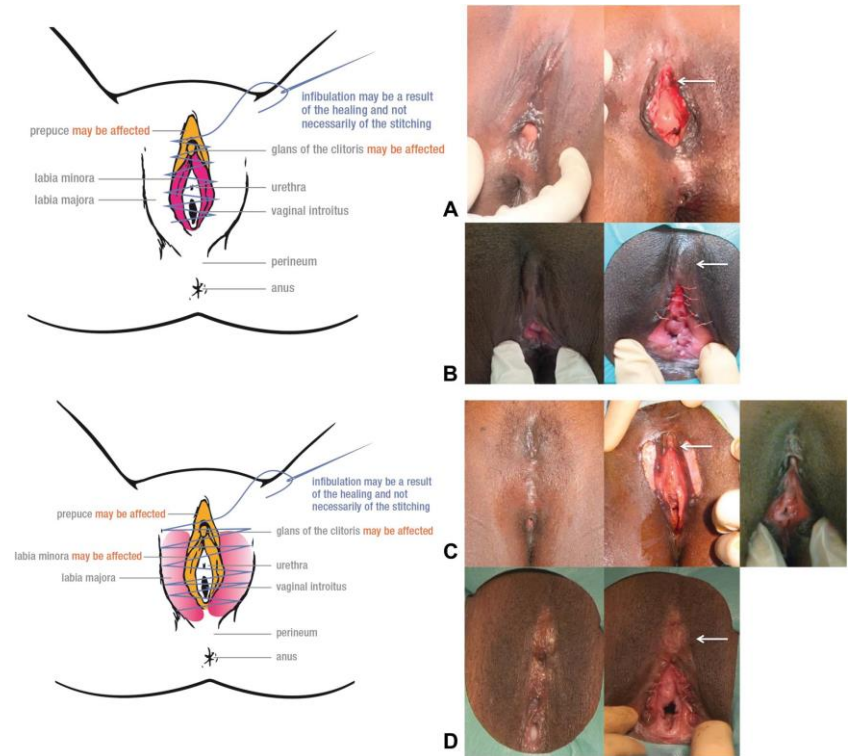
Female genital mutilation type II: partial or total removal of the clitoris and the labia minora with or without excision of the labia majora (excision).



Female Genital Mutilation: A Visual Reference and Learning Tool for Health Care Professionals. Abdulcadir, Jasmine; Catania, Lucrezia; Hindin, Michelle; Say, Lale; Petignat, Patrick; Abdulcadir, Omar *Obstetrics & Gynecology*. 128(5):958-963, November 2016. DOI: 10.1097/AOG.0000000000001686 authorized by Abdulcadir

Female genital mutilation type II: partial or total removal of the clitoris and the labia minora with or without excision of the labia majora (excision). A. Female genital mutilation type IIa: removal of the labia minora only. B. Female genital mutilation type IIb: partial or total removal of the clitoris and the labia minora. C. Female genital mutilation type IIc: partial or total removal of the clitoris, the labia minora, and the labia majora

Female genital mutilation type III: narrowing of the vaginal orifice with creation of a covering seal by cutting and appositioning the labia minora or the labia majora or both, with or without excision of the clitoris (infibulation).



Female Genital Mutilation: A Visual Reference and Learning Tool for Health Care Professionals. Abdulcadir, Jasmine; Catania, Lucrezia; Hindin, Michelle; Say, Lale; Petignat, Patrick; Abdulcadir, Omar *Obstetrics & Gynecology*. 128(5):958-963, November 2016. DOI: 10.1097/AOG.0000000000001686 authorized by Abdulcadir

Female genital mutilation type III: narrowing of the vaginal orifice with creation of a covering seal by cutting and appositioning the labia minora or the labia majora or both, with or without excision of the clitoris (infibulation). A. Female genital mutilation type IIIa without cutting of the clitoris before and after defibulation, the surgery that opens infibulation. Arrow: intact clitoris uncovered after defibulation. B. Female genital mutilation type IIIa with cutting of the clitoris before and after defibulation. Arrow: clitoral stump visible under the scar. C. Female genital mutilation type IIIb without cutting of the clitoris before and after defibulation. Arrow: intact clitoris uncovered after defibulation. D. Female genital mutilation type IIIb with cutting of the clitoris before and after defibulation. Arrow: clitoral stump visible under the scar. When the clitoris is excised, the clitoral stump is palpable and sometimes visible under the scar. When the clitoris is not excised, it lies under the scar and is re-exposed during defibulation.